

# Reload of oral steroid on acute posterior multifocal placoid pigment epitheliopathy

*by* Habibah Muhiddin

---

**Submission date:** 24-Jun-2021 05:40AM (UTC+0700)

**Submission ID:** 1611285759

**File name:** acute\_posterior\_multifocal\_placoid\_pigment\_epitheliopathy1-2.pdf (696.22K)

**Word count:** 2309

**Character count:** 13058

## CASE REPORT

## PEER REVIEWED | OPEN ACCESS

# Reload of oral steroid on acute posterior multifocal placoid pigment epitheliopathy

Andi Muhammad Ichsan, Deby Trisnawaty Mansyur,  
Habibah Setyawati Muhiddin, Budu

## ABSTRACT

**Introduction:** Acute posterior multifocal placoid pigment epitheliopathy (APMPPE) is a retinal disease which is often preceded by flu-like illness and sudden vision loss associated with central and paracentral scotomas. The disease is funduscopically characterized with multifocal flat yellowish-white lesion at the level of retinal pigment epithelium (RPE) associated with macular edema. The aim of this article is to report a case of APMPPE that was successfully treated with oral steroid. **Case Report:** A 28-year-old woman presented with suddenly decrease in her visual acuity in both eyes from three days. She experienced mild fever and malaise a week ago. Best-corrected visual acuities (BCVA) were 20/70 in the right eye (RE) and 20/80 in the left eye (LE). Anterior segment was normal except conjunctival hyperemia in both eyes. Ophthalmoscopy examination showed multiple sub-retinal yellowish-white placoid lesion and edema with slight detachment of macula at the level of retinal pigment epithelium. Fluorescein fundus angiography showed initially with hypofluorescein followed by hyperfluorescein with multiple placoid lesions after several minutes in both eyes. Optical coherence

tomography (OCT) revealed epithelial and retinal detachment on both eyes. Initial treatment with oral steroid 48 mg/day for one week then tapered every three days to dose of 2 mg/day, the patient gained a clinical improvement and better visual acuity but again VA dropped to 20/70 in the RE and 20/60 in the LE when dose was nearly ended. Therefore, the oral steroid was reloaded from its initial dose for one week and tapered every one week. Three weeks follow-up period showed improvement with BCVA 20/25 and 20/30 in the RE and LE respectively and she remained stable after steroid therapy was completely end. **Conclusion:** This case showed that treatment APMPPE with single oral steroid resolved the macular thickness leading to visual acuity improvement.

**Keywords:** Acute posterior multifocal placoid pigment epitheliopathy, Oral steroid, White dot syndrome

### How to cite this article

Ichsan AM, Mansyur DT, Muhiddin HS, Budu. Reload of oral steroid on acute posterior multifocal placoid pigment epitheliopathy. J Case Rep Images Ophthalmol 2018;1:100003Z17AI2018.

Article ID: 100003Z17AI2018

\*\*\*\*\*

doi: 10.5348/100003Z17AI2018CR

Andi Muhammad Ichsan<sup>1,2</sup>, Deby Trisnawaty Mansyur<sup>1</sup>,  
Habibah Setyawati Muhiddin<sup>1,2</sup>, Budu<sup>1,2</sup>

**Affiliations:** <sup>1</sup>Department of Ophthalmology, Faculty of Medicine, Hasanuddin University, Makassar, Indonesia; <sup>2</sup>Celebes Eye Center "Orbita", Makassar, Indonesia.

**Corresponding Author:** Andi Muhammad Ichsan, Department of Ophthalmology, Faculty of Medicine, Hasanuddin University, Makassar, Indonesia; Email: am\_ichsan@yahoo.com

Received: 09 June 2018  
Accepted: 24 July 2018  
Published: 09 August 2018

## INTRODUCTION

White dot syndrome is defined as a group of idiopathic multifocal inflammatory conditions characterized by appearance of yellow-white patches on the fundus,

involving the retina and the choroid. This disease comprises of acute posterior multifocal placoid pigment epitheliopathy (APMPPE), birdshot chorioretinopathy, multiple evanescent white dot syndrome (MEWDS), acute zonal occult outer retinopathy (AZOOR), multifocal choroiditis and panuveitis (MCP), punctate inner choroiditis (PIC), and serpiginous choroiditis [1].

The disease usually manifests with a sudden onset of visual blurring or flashing lights in a patient younger than 30 years of age without sex predilection. Older patients have occasionally been reported. In some patients, flashing lights precede the visual loss by several weeks [2].

The pathogenesis of APMPPE remains unclear. A delayed type hypersensitivity associated vasculitis suspected as the main cause of APMPPE [3]. Vasculitis then affects the choroidal terminal lobules and systemic vasculature causing obstruction at the level of the choroidal terminal lobules and then induce ischemic changes in the outer layers of the macula. Vasculitis mechanism is supported by the association of APMPPE with other vasculitis (cerebral angiitis, thyroiditis, nephropathies, and erythema nodosum) [3, 4].

## CASE REPORT

A 28-year-old female patient presented with sudden vision loss in both eyes for three days. Initially left eye and then followed the right eye. There was history of mild fever and malaise for a week. Initial visual acuities were 20/70 and 20/80 in right and left eye respectively. Normal anterior segment was found except of conjunctival hyperemia. Fundus examination showed multiple sub-retinal yellowish-white placoid lesions, predominantly at the posterior pole of retina Figure 1 (A–D). A dome shape of macula or retinal pigment epithelial in the both eyes. The early phase of fluorescein fundus angiography (FFA) showed hypofluorescein followed by hyperfluorescein with multiple placoid lesions after several minutes in both eyes Figure 2(A–D). Optical coherence tomography (OCT) of central region on right eye demonstrated exudative detachment of retinal pigment epithelium. Similar condition was found in the left eye with central macular thickness was 405 μm (Figure 3).

Oral Steroid therapy was started with methylprednisolone (1 mg/kg/day) 48 mg/day for one week then tapered every three days, but after up to dose of 2 mg/day, the visual acuity dropped to 20/70 and 20/60 in right and left eye respectively. Therefore, the oral steroids reload from initial dose (48 mg/day) for one week and tapered every single week. Three weeks follow-up period showed improvement of visual acuity to be 20/25 and 20/30 in the right and left eye Figure 4(A–D). Clinical and anatomical improvement was confirmed by OCT examination.

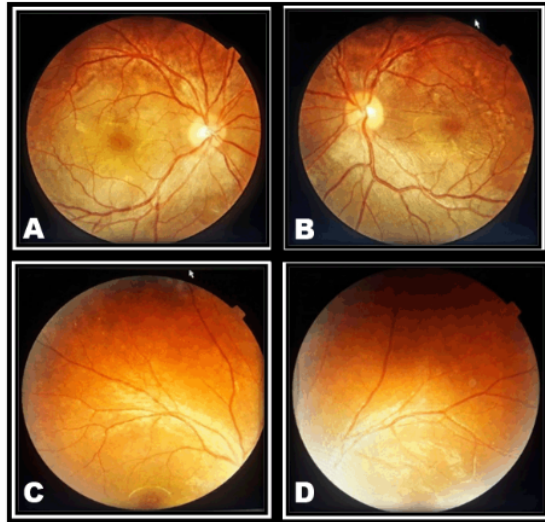


Figure 1(A–D): Fundus photograph of A and B showed multifocal placoid yellowish at the posterior pole of retina. Multiple yellowish-white placoid lesions, predominantly at the midperiphery the right (C) and the left (D) of retina.

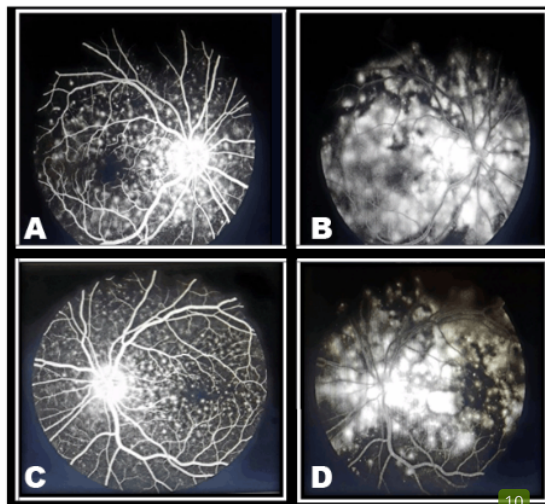


Figure 2(A–D): Fluorescein fundus angiography (FFA) in the early phase hypofluorescein of the right eye (A) and left eye (C), then became diffuse hyperfluorescein of the right eye (B) and left eye (D) at the level RPE.

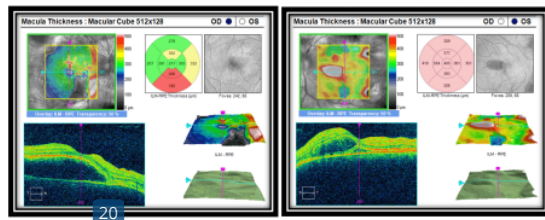


Figure 3: Optical coherence tomography of right and left eye showed exudative detachment of retinal pigment.

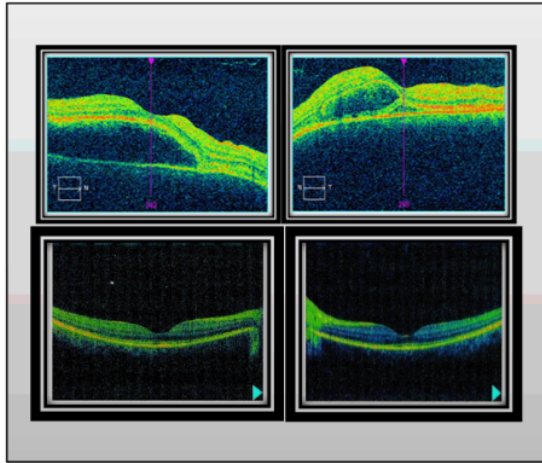


Figure 4(A–D): Complete resolution of subretinal fluid after treatment with oral steroid (C) and (D) of right and left eye compared with before treatment (A and B) confirmed by Optical coherence tomography.

## DISCUSSION

The diagnosis of acute posterior multifocal placoid pigment epitheliopathy is principally clinical, and is based on examination of the posterior pole and on the progression of the symptoms over time. In our case, the diagnosis was confirmed by clinical findings such as visual deficiency accompanied by the presence of plaque-like lesions which were found by indirect ophthalmoscopy examination, the presence of hypofluorescein areas in early phase then hyperfluorescein which is the characteristic of this disease.

Furthermore, white dot syndromes along with other conditions come into the differential diagnosis of this disease, include serpiginous choroidopathy which should be considered in recurrent, chronic cases, relentless placoidchorioretinitis which should be taken into account in severe and recurrent cases still possible in this patient, MEWDS, Birdshot, and sarcoidosis [2].

Gass described the early-phase lesions as hypofluorescein, and later on in the study there is progressive, irregular hyperfluorescein staining of the lesions the has been mentioned above was a hallmark in our patient's fluorangiographic examination. As the process becomes inactive, hyperfluorescein can be seen corresponding to window defects in the pigmented epithelium of the retina where the staining phenomenon is no longer evident [5, 6].

With regard to the existing connection between this disease and HLA-B7 and HLA-DR2 positivity, it is possible to assume that a genetic predisposition exists [6, 7]. HLA-B7 and HLA-DR2 were not examined because of psychological trauma of the patient's experience due to side effects of FFA examination.

Initial treatment of oral steroid therapy 48 mg/day was given for one week then tapered every three days. Visual acuity started to improve after several days but after tapered dose of 2 mg/day, the visual acuity decreased again to 20/70 and 20/180 in right and left eye. Visual prognosis of APMPE affected by the presence of initial foveal involvement. Flore et al reported full recovery only has been in 53% of eyes with initial foveal involvement and in 88% of eyes without initial foveal involvement [8].

Jabs et al published a guideline based on clinical studies that were rated according to the quality and strength of available evidence to treat. The guideline uses prednisone as the main therapy for chronic ocular inflammation, starting from 1 mg/kg/day and then tapered every 1–2 weeks [9]. Based on this guideline, we suggest that the reduction of visual acuity caused by rapid tapering of the steroid treatment and also by severity of this case with RPE detachment. Therefore, the oral steroids were reloaded—started again from initial dose (48 mg/day) for one week and then tapered every one week. After three weeks follow-up period, the visual acuity showed improvement to BCVA 20/25 and 20/30 in the right and left eye, confirmed by improvement in OCT examination.

The use of steroid therapy remains controversial. Some authors believe that steroid therapy would be useful to shorten the duration of visual recovery in some cases. Tanigawa et al reported a case of APMPE without systemic association that has been treated with combined intravenous methylprednisolone (1000 mg/day for 3 days) followed by oral prednisolone for 17 weeks. Macular lesion was also found in this case [10]. Different from our case, this showed prolonged visual recovery until six months of therapy.

Immunosuppressants and intravenous steroids were recommended in cases with systemic associations, such as inflammation of the central nervous system. Çomu et al suggested stopping immunosuppressive therapy after 6–12 months. Steroid was used for 2–3 months and azathioprine as immunosuppressive therapy for 12 months, which closed monitoring of ophthalmological and neurological evaluations should be performed at 3-month intervals [11].

## CONCLUSION

Steroid therapy for APMPE remains controversial since APMPE has been known to resolve spontaneously. This case showed that treatment APMPE with single oral steroid resolved the macular thickness leading to visual acuity improvement. Mind the time for tapering the steroid therapy, since rapid tapering may leads to reactivation of disease. In this case, reloaded therapy can be done and showed satisfactory response.

**REFERENCES**

1. Chandrakar N, Bajaj P, Sharma R, Kumar V. Acute posterior multifocal placoid pigment epitheliopathy (APMPPE): A case report. *Delhi J Ophthalmol* 2017;28:41-2.
2. Nussenblatt RB, Whitcup SM. White dot syndrome. In: Nussenblatt RB, Whitcup SM, editors. *Uveitis: Fundamentals and Clinical Practice*. St. Louis: Mosby; 2004. p. 398-401.
3. Senanayake SN, Selvadurai S, Hawkins CA, Tridgell D. Acute multifocal placoid pigment epitheliopathy associated with erythema nodosum and a flu-like illness. *Singapore Med J* 2008 Nov;49(11):e333-5.
4. Daniel B, and Andrei B. Acute posterior multifocal placoid pigment epitheliopathy following influenza vaccination. *Rom J Ophthalmol* 2015 Jan-Mar;59(1):52-8.
5. Gass JD. Acute posterior multifocal placoid pigment epitheliopathy. *Arch Ophthalmol* 1968;80:177-86.
6. Hernández-Da Mota SE. Acute posterior multifocal placoid pigment epitheliopathy: Case report. [Article in Spanish]. *Cir Cir* 2016 Mar-Apr;84(2):135-9.
7. Algahtani H, Alkhotani A, Shirah B. Neurological manifestations of acute posterior multifocal placoid pigment Epitheliopathy. *J Clin Neurol* 2016 Oct;12(4):460-7.
8. Fiore T, Iaccheri B, Androudi S, et al. Acute posterior multifocal placoid pigment epitheliopathy: Outcome and visual prognosis. *Retina* 2009 Jul-Aug;29(7):994-1001.
9. Jabs DA, Rosenbaum JT, Foster CS, et al. Guidelines for the use of immunosuppressive drugs in patients with ocular inflammatory disorders: Recommendations of an expert panel. *Am J Ophthalmol* 2000 Oct;130(4):492-513.
10. Tanigawa M, Tsukahara Y, Yamanaka H. A case of acute posterior multifocal placoid pigment epitheliopathy demonstrating vogt-koyanagi-harada disease-like optical coherence tomography findings in the acute stage. *Case Rep Ophthalmol* 2013 Oct 11;4(3):172-9.
11. Comu S, Verstraeten T, Rinkoff JS, Busis NA. Neurological manifestations of acute posterior multifocal placoid pigment epitheliopathy. *Stroke* 1996 May;27(5):996-1001.

\*\*\*\*\*

**Author Contributions**

Andi Muhammad Ichsan – Substantial contributions to conception and design, Acquisition of data, Analysis and interpretation of data, Drafting the article, Revising it critically for important intellectual content, Final approval of the version to be published  
 Deby Trisnawaty Mansyur – Substantial contributions to conception and design, Acquisition of data, Analysis and interpretation of data, Drafting the article, Revising it critically for important intellectual content, Final approval of the version to be published  
 Habibah Setyawati Muhiddin – Substantial contributions to conception and design, Drafting the article, Revising it critically for important intellectual content, Final approval of the version to be published  
 Budu – Substantial contributions to conception and design, Drafting the article, Revising it critically for important intellectual content, Final approval of the version to be published

**Guarantor of Submission**

The corresponding author is the guarantor of submission.

**Source of Support**

None.

**Consent Statement**

Written informed consent was obtained from the patient for publication of this case report.

**Conflict of Interest**

Authors declare no conflict of interest.

**Copyright**

© 2018 Andi Muhammad Ichsan et al. This article is distributed under the terms of Creative Commons Attribution License which permits unrestricted use, distribution and reproduction in any medium provided the original author(s) and original publisher are properly credited. Please see the copyright policy on the journal website for more information.

# Reload of oral steroid on acute posterior multifocal placoid pigment epitheliopathy

## ORIGINALITY REPORT

24%

SIMILARITY INDEX

18%

INTERNET SOURCES

19%

PUBLICATIONS

1%

STUDENT PAPERS

## PRIMARY SOURCES

1	<a href="http://www.elsevier.es">www.elsevier.es</a> Internet Source	7%
2	<a href="http://www.healio.com">www.healio.com</a> Internet Source	3%
3	<a href="http://www.cs-ophthalmology.cz">www.cs-ophthalmology.cz</a> Internet Source	2%
4	<a href="http://lookformedical.com">lookformedical.com</a> Internet Source	2%
5	Sergio Eustolio Hernández-Da Mota. "Acute posterior multifocal placoid pigment epitheliopathy", Cirugía y Cirujanos (English Edition), 2016 Publication	1%
6	<a href="http://partnerkatestow.ru">partnerkatestow.ru</a> Internet Source	1%
7	"From the 8th European Neuro-Ophthalmology Society (EUNOS) Meeting", Neuro-Ophthalmology, 2007. Publication	1%

8	<p>Angel Salinas-Alaman. "Retinal neovascularization and vitreous haemorrhage in a patient with acute myeloid leukaemia and haematopoietic stem cell transplantation", <i>Acta Ophthalmologica Scandinavica</i>, 8/2003</p> <p>Publication</p>	1 %
9	<p>"Correction", <i>British Journal of Ophthalmology</i>, 8/1/2002</p> <p>Publication</p>	1 %
10	<p>Ranko Aoyagi, Takaaki Hayashi, Tamaki Gekka, Kenichi Kozaki, Hiroshi Tsuneoka. "Multifocal electroretinographic evaluation of macular function in acute posterior multifocal placoid pigment epitheliopathy", <i>Documenta Ophthalmologica</i>, 2013</p> <p>Publication</p>	1 %
11	<p>Quillen, D.A.. "The white dot syndromes", <i>American Journal of Ophthalmology</i>, 200403</p> <p>Publication</p>	1 %
12	<p><a href="http://www.ryumachi-jp.com">www.ryumachi-jp.com</a></p> <p>Internet Source</p>	1 %
13	<p><a href="http://bmcoophthalmol.biomedcentral.com">bmcoophthalmol.biomedcentral.com</a></p> <p>Internet Source</p>	<1 %
14	<p>S Pagliarini. "Foveal involvement and lack of visual recovery in APMPE associated with uncommon features", <i>Eye</i>, 01/1995</p> <p>Publication</p>	<1 %

15	dokumen.pub Internet Source	<1 %
16	Denize Atan, Samantha Fraser-Bell, Jarka Plskova, Lucia Kuffová et al. " Punctate Inner Choroidopathy and Multifocal Choroiditis with Panuveitis Share Haplotypic Associations with and Loci ", Investigative Ophthalmology & Visual Science, 2011 Publication	<1 %
17	Nakhleh E. Abu-Yaghi, Stella P. Hartono, David O. Hodge, Jose S. Pulido, Sophie J. Bakri. "White Dot Syndromes: A 20-year Study of Incidence, Clinical Features, and Outcomes", Ocular Immunology and Inflammation, 2011 Publication	<1 %
18	TITO FIORE. "ACUTE POSTERIOR MULTIFOCAL PLACOID PIGMENT EPITHELIOPATHY", Retina, 07/2009 Publication	<1 %
19	R H Gray. "Unilateral enlargement of the blind spot: a diagnostic dilemma", British Journal of Ophthalmology, 2002 Publication	<1 %
20	Manual of Retinal Diseases, 2016. Publication	<1 %
21	Sumru Onal, Ilknur Tugal-Tutkun, Piergiorgio Neri, Carl P Herbort. "Optical coherence	<1 %

# tomography imaging in uveitis", International Ophthalmology, 2013

Publication

---

---

Exclude quotes      On

Exclude matches      < 5 words

Exclude bibliography      On